

# The Role of Subchondral Bone in Joint Disease

Christopher E. Kawcak, DVM, PhD, Diplomate ACVS;  
C. Wayne McIlwraith, BVSc, PhD, FRCVS, Diplomate ACVS;  
Richard D. Park, DVM, PhD; and S. P. James, PhD

There is evidence to suggest that osteochondral diseases in the athletic horse start as chronic processes which culminate in clinical disease. Authors' addresses: Equine Orthopaedic Research Laboratory (Kawcak and McIlwraith), Department of Radiological Health Sciences (Park), College of Veterinary Medicine and Biomedical Sciences, and Department of Mechanical Engineering (James), College of Engineering, Colorado State University, Fort Collins, CO 80523. © 2001 AAEP.

## 1. Introduction

Subchondral bone plays a role in the pathogenesis of osteochondral damage and osteoarthritis in horses and humans. Osteochondral fragmentation and fracture, subchondral bone necrosis, and osteoarthritis are common diseases in athletic horses, and subchondral bone is now thought to play an integral role in the pathogenesis of these diseases. There have been numerous research efforts focused on articular cartilage damage and its pathogenesis, yet comparatively little effort has been focused on subchondral bone pathology, or the coordinated disease states of the osteochondral tissues. The purpose of this report is to review the current understanding of osteochondral disease in all species and its application to equine research and practice. It can be concluded from this review that our current un-

derstanding of osteochondral disease is based on clinical and pathologic sources, and that the lack of information about joint tissue adaptation and disease has hampered objective studies of osteochondral tissues.

## 2. Osteochondral Tissues

The tissues that compose and support joint surfaces are collectively called *osteochondral tissues*. The most superficial of these, the articular cartilage, is essential for absorbing shock and maintaining normal joint environment, and, regardless of the cause, degeneration of articular cartilage can result in irreversible osteoarthritis.<sup>1</sup> The subarticular tissues include calcified cartilage, which provides a transition between the stiff subchondral bone and the compliant articular cartilage, and subchondral bone, which can be further classified into the subchondral bone plate and the trabecular bone (Fig. 1). The subchondral bone plate is defined here as the bone layer separating the calcified cartilage from the marrow spaces.<sup>2</sup>

Osteochondral tissues also contain blood vessels and marrow spaces. Vascular channels connect the

---

Supported by grants from the American Quarter Horse Association, Morris Animal Foundation, and the Ken Atkinson Graduate Scholarship. Portions of this paper were reproduced from Kawcak CE, et al. The role of subchondral bone in joint disease: a review. *Equine Vet J* 2001;33:120-126.

---

## NOTES

## IN DEPTH: CURRENT CONCEPTS IN EQUINE OSTEOARTHRITIS

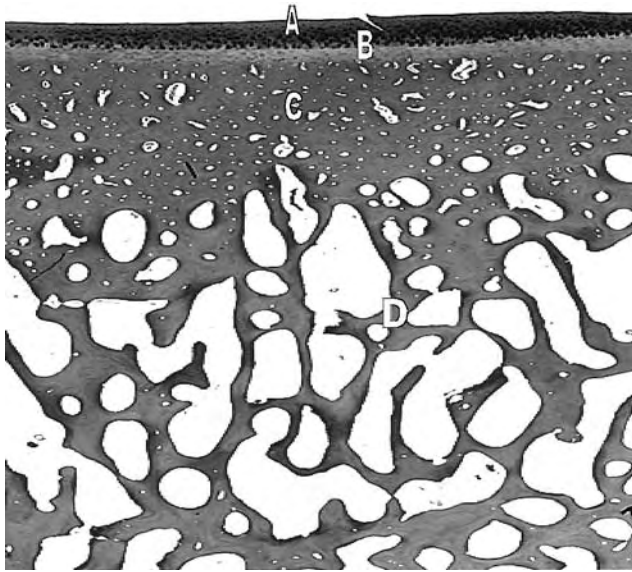


Fig. 1. A histologic section of the osteochondral area demonstrating articular cartilage (A), calcified cartilage (B), subchondral bone plate (C), and trabecular bone (D).

marrow spaces of trabecular bone with the calcified cartilage layer, thus nourishing the deeper cartilage layers that cannot be nourished by synovial fluid.<sup>3,4</sup> These vascular channels also nourish osteocytes in the subchondral bone plate, unlike osteocytes in trabecular bone, which receive nourishment from marrow tissue.

#### Response of Subchondral Bone to Loading

Subchondral bone density and strength adapt to imposed stresses. For instance, the third carpal bone and the palmar aspect of the third metacarpal condyle of horses can become thickened in response to training, even to the point that the sclerosis is considered pathologic (Fig. 2).<sup>5</sup> Modeling and remodeling control this adaptive response. Bone

modeling is defined as bone formation or resorption at a given site to produce "functionally and mechanically purposeful architecture."<sup>6</sup> This can occur at the organ level (macromodeling) or at the trabecular level (minimodeling).<sup>6</sup> In both cases, bone formation and resorption are independent so as to cause bone drifts. In remodeling, however, packets of bone are removed and then replaced so as to replace damaged bone.<sup>6,7</sup>

The processes of modeling and remodeling are hypothesized to be driven by bone strain. At the "optimal strain environment," bone formation and resorption are quiescent. However, resorption will occur below the minimum strain threshold and bone formation will occur above the maximum strain threshold.<sup>6,8</sup> Bone formation is also dictated by strain rate. For instance, unlike static strain, short bursts of dynamic strain increase bone formation.<sup>8</sup> Therefore, the magnitude, rate, and duration of an applied load drive bone formation.

The mechanism by which strain induces bone change is unknown. Bone matrix microdamage has been shown experimentally to stimulate bone remodeling.<sup>9,10</sup> At the light microscopic level using basic fuchsin stain, microdamage can occur in 2 forms, microcracks and diffuse microdamage.<sup>10-12</sup> Microcracks appear as matrix defects in which the surrounding matrix stains with the dye (Fig. 3).<sup>11</sup> Diffuse microdamage is seen as areas of stained matrix without the defect (Fig. 3).<sup>12</sup>

Osteocytes may also play a role in the response of bone to strain. For instance, Noble et al have shown increased osteocyte apoptosis (cell death) in highly remodeling bone, such as infant calvaria and osteophytes. They theorized that loss of osteocyte viability may lead to increased osteoclastic function.<sup>13</sup> Qiu et al further showed that the number of apoptotic cells increased around areas of experimentally induced bone microdamage, which later lead to increased bone remodeling.<sup>14</sup> Osteocyte viability, which can be assessed by staining for lac-

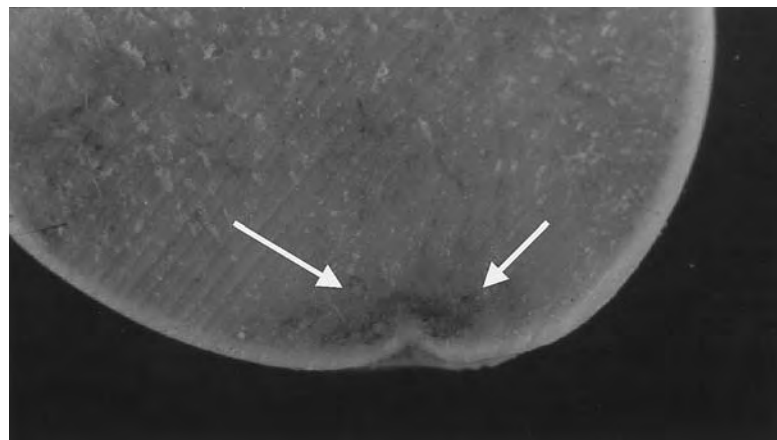


Fig. 2. An osteochondral section of a third metacarpal condyle from a racehorse demonstrating subchondral bone necrosis and collapse (arrows).

## IN DEPTH: CURRENT CONCEPTS IN EQUINE OSTEOARTHRITIS

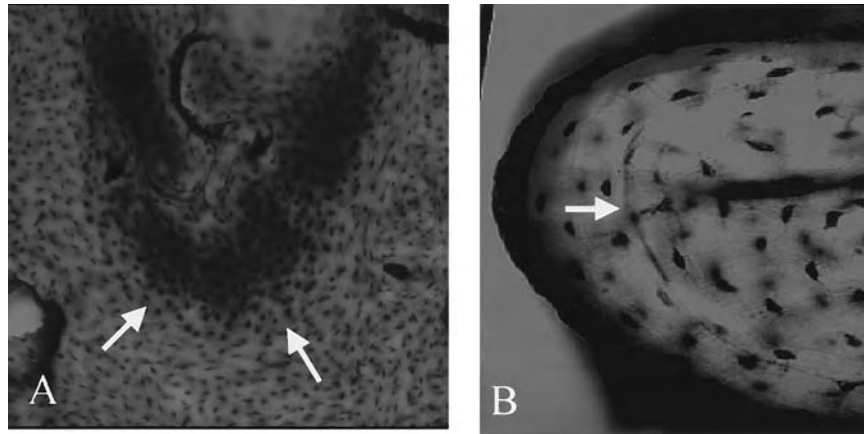


Fig. 3. Histologic sections stained with basic fuchsin demonstrating diffuse microdamage (A) and a microcrack (B).

tate dehydrogenase in freshly cut bone sections (Fig. 4), is decreased in the femoral heads of patients with idiopathic hip osteoarthritis<sup>15</sup> and femoral head fracture.<sup>16</sup> Therefore, osteocyte viability may play a role in response of subchondral bone to stress and in the pathogenesis of joint disease.

#### Subchondral Bone Function

Subchondral bone has two main functions—stress absorption and maintenance of joint shape. Subchondral bone provides the majority of the cushioning for the joint because it is more abundant than the more compliant articular cartilage, and has a relatively low modulus of elasticity.<sup>17,18</sup> However, a balance between bone that has appropriate strength and appropriate cushioning ability is necessary to maintain a normal joint environment.<sup>19,20</sup> All joints normally show a variation in the density and thickness of subchondral bone across the joint surface, and consequently a variation in the mechanical

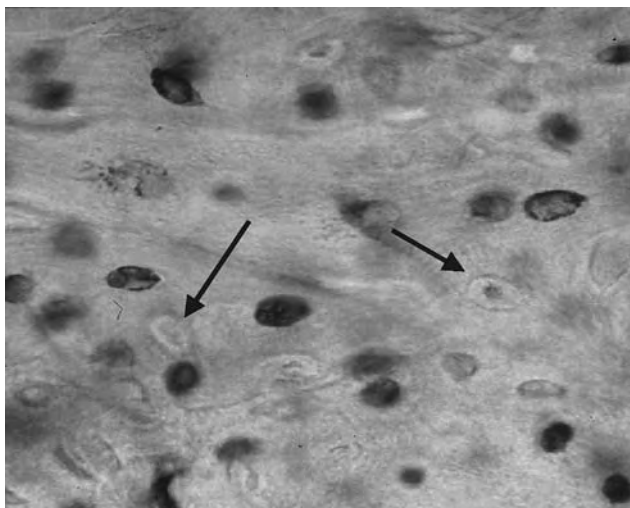


Fig. 4. An osteochondral section demonstrating nonviable osteocytes as unstained cells with only the lacunae showing (arrow).

properties at each site.<sup>21</sup> Stress to cancellous bone is thought to cause buckling of trabeculae,<sup>22</sup> which may further relieve the stress through the bone or induce microdamage and remodeling to strengthen bone.<sup>23</sup> Therefore, cushioning ability dynamically changes with imposed stresses.

The second function of subchondral bone is to provide the means to maintain an incongruent joint surface, which is ideal for maintaining a physiological joint environment.<sup>24</sup> Incongruent joint surfaces have outer surfaces that maintain contact while the surfaces in the center of the joint remains separated (Fig. 5). This allows for the center of the joint to move axially during loading, transmitting stresses to the cortical bone, and maintaining nourishment to the superficial layer of articular cartilage.<sup>24</sup> This shape is thought to develop in utero by the forces placed on the joint by tendon insertions,<sup>25</sup> and is maintained after birth by the normal physiological forces that are applied across the joint. Pathologic forces may therefore pose a threat to the normal physiologic balance that maintains joint shape and cushioning ability.

Although the shape of a particular joint is genetically predetermined, the structural features result from the loading history of the joint.<sup>2</sup> Results of computed tomographic osteoabsorptiometry (a three-dimensional representation of the surface density of subchondral bone) have shown that joint surface density was an indicator of loading history in both normal and diseased human shoulder joints.<sup>2</sup>

### 3. Subchondral Bone Disease in Humans

Osteoarthritis has been defined as organ failure of a joint due to mechanical factors, causing loss of articular cartilage and inducing subchondral bone sclerosis.<sup>1</sup> Some investigators have hypothesized that thinning of articular cartilage is due to advancement of the tidemark from reactivation of the secondary centers of ossification.<sup>1</sup> This calcified cartilage and subchondral bone remodeling has been

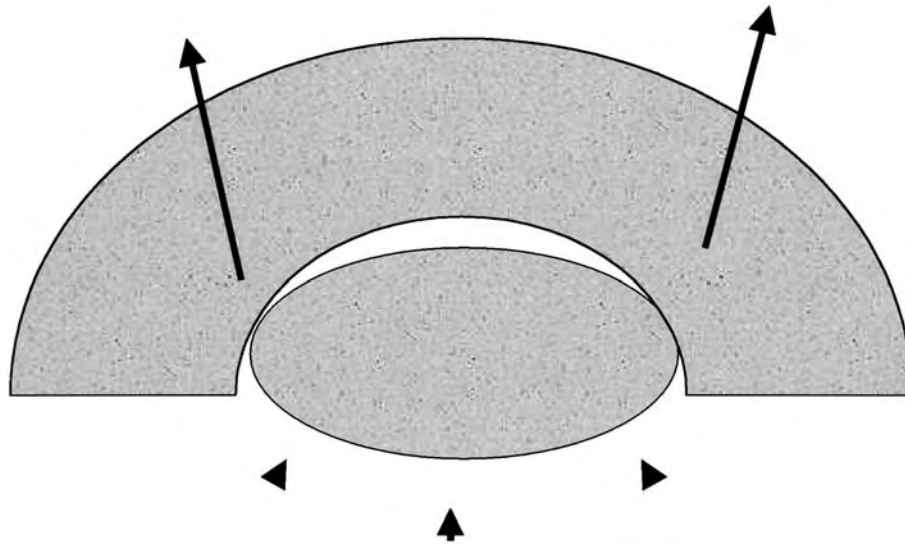


Fig. 5. A schematic demonstrating an incongruent joint surface with the imposed load (arrowheads) leading to subchondral bone bending and transfer of the load to the cortical bone (arrows).

demonstrated by increased vascular invasion, increased mineralization around vascular channels, calcified cartilage thickening, and duplication of the tidemark.<sup>1</sup>

Microdamage in calcified cartilage and subchondral bone may be responsible for initiating remodeling. Microdamage has been seen in the calcified cartilage layer of human hip specimens at autopsy.<sup>26,27</sup> Sokoloff also found an association of microdamage with remodeling centers in the calcified cartilage layer of osteoarthritic joints.<sup>27</sup>

Debate continues as to the initial event(s) that causes osteoarthritis. Some investigators contend that articular cartilage changes precede subchondral bone changes; while other investigators contend the opposite.<sup>28,29</sup> It appears that changes in articular cartilage and subchondral tissues are so intertwined that distinguishing a single initiating change in either tissue is difficult. Radin and coworkers were some of the first to theorize that osteoarthritic changes start in the subchondral mineralized tissues—both calcified cartilage and subchondral bone.<sup>1</sup> They showed experimentally in rabbits that osteoarthritic changes—namely, articular cartilage erosion—could be induced with 8 weeks of impulsive loading of the tibia followed by 24 weeks of rest.<sup>30</sup> When studied after 6 weeks of loading, increases in calcified cartilage thickness and subchondral bone remodeling were seen, but there were no changes in articular cartilage proteoglycan properties, including size and concentration of proteoglycans and synthetic rate of glycosaminoglycans.<sup>30,31</sup> Therefore, this model shows that subchondral bone changes early in the course of osteoarthritis.

#### 4. Subchondral Bone Disease in Horses

Pathologic studies on the subchondral bone of racehorses have shown evidence that the subchondral

bone becomes denser in response to exercise.<sup>5</sup> Young et al have shown that the material properties (stiffness) and percent bone area of the third carpal bones of horses increased in response to exercise.<sup>32</sup> More specifically, they showed good correlation between percent bone area and stiffness, with the greatest increase occurring approximately 10 mm from the dorsal margin of the radial facet of the third carpal bone.<sup>32</sup> In a different study, Young et al also showed that bone formation increased in the proximal sesamoid bones of horses in response to exercise.<sup>33</sup> These studies show that subchondral bone responds to the stress of exercise by increasing bone formation in an attempt to increase strength.

Estberg et al have shown a cause-effect relationship between the intensity of exercise and injury in racehorses.<sup>34</sup> They showed that Thoroughbred racehorses that worked at long distances at high speeds, or that rapidly achieved high speeds over a short period of time were more likely to acquire musculoskeletal injury than horses at lower exercise intensities.<sup>34</sup> Therefore, similar to humans and experimental models, exercise can have varying effects on joints, depending on the intensity and duration of exercise.

Racehorses exhibit tremendous changes within the subchondral bone of their carpal and metacarpophalangeal joints. Diseases in these joints can range in severity from simple osteochondral fragmentation,<sup>35-37</sup> to complete osteochondral fracture,<sup>38-42</sup> to life-threatening “catastrophic” fractures that result in complete loss of support of the affected limb.<sup>43-45</sup> In addition to fractures, intense subchondral bone sclerosis and consequently, joint damage, (i.e., osteoarthritis) are common to young racehorses.<sup>5,40,46,47</sup> These injuries account for the majority of horse wastage in the racehorse indus-

## IN DEPTH: CURRENT CONCEPTS IN EQUINE OSTEOARTHRITIS

try,<sup>48,49</sup> and removal of horses from racing prior to productive years.<sup>50</sup>

Osteochondral fragmentation and complete articular fractures are common in young racehorses and the severity of damage determines the prognosis for return to full function.<sup>35-37</sup> Osteochondral fragmentation, in which fragments of articular cartilage and subchondral bone at the joint margin detach from the parent bone, occurs within several bones of the carpal and metacarpophalangeal joints. The reason for their involvement is theorized to be due to high loads experienced by these bones and joint surfaces, extreme hyperextension of the carpus with exercise, and immaturity of bones in young horses.<sup>51</sup> Osteochondral fragmentation of the proximal aspect of the first phalanx is also a common problem, especially for Thoroughbred racehorses.<sup>36,37</sup> Extreme hyperextension of the metacarpophalangeal joint is theorized to result in repeated loading of this site, especially on the medial aspect where the lesions are most typically seen.<sup>36,37</sup>

Complete osteochondral fractures occur within the third carpal bone of the carpus,<sup>40,41</sup> the distal third metacarpal condyle,<sup>38</sup> and the proximal sesamoid bones of the metacarpophalangeal joint.<sup>39,42</sup> Complete articular or "slab" fractures of the third carpal bone can result in acute, painful lameness that requires internal fixation for healing and return to function.<sup>41</sup> Complete articular or "condylar" fractures of the distal third metacarpal bone commonly occur in Thoroughbred racehorses and often require internal fixation for repair. These fractures can range in severity from small, incomplete fractures,<sup>52</sup> to large, displaced fractures with fragmentation.<sup>46</sup> This spectrum of damage has prompted some to hypothesize that these fractures may result from cyclic damage.<sup>5</sup> Support for this hypothesis comes from a study in which microdamage formation was seen at these sites in non-fractured, post-mortem specimens.<sup>53</sup> Further support also comes from Riggs et al, who showed that linear defects existed in the mineralized articular cartilage of racehorses and was in an area with a high density gradient.<sup>54</sup> Complete articular fractures of the proximal sesamoid bones can result in simple fractures that are easily removed arthroscopically,<sup>39</sup> to life-threatening, complete, biaxial fractures that result in loss of metacarpophalangeal joint support and damage to the vascular supply to the digit.<sup>5</sup> Loss of blood supply to the digit often results in laminitis and loss of the hoof capsule, consequently leading to euthanasia. Proximal sesamoid bones have shown a considerable remodeling response to training,<sup>33</sup> but the formation of microdamage at these sites has not been determined.

Subchondral bone sclerosis and osteoarthritis occurs within the carpal<sup>5,47</sup> and metacarpophalangeal joints of racehorses.<sup>5,46</sup> Sclerosis of the third carpal bone in racehorses is commonly associated with

lameness that impedes performance.<sup>47</sup> Studies investigating this problem show that the radial facet of the third carpal bone must undergo significant bone formation in order to withstand the forces of training and racing.<sup>47</sup> Severe sclerosis, though, was seen in 90% of horses with complete osteochondral fractures of the third carpal bone,<sup>40</sup> and has led some to hypothesize that intense sclerosis leads to increased stiffness, and consequently fracture and articular cartilage damage.<sup>40</sup> Similar problems occur within the palmar condylar surface of the distal third metacarpus in the metacarpophalangeal joint.<sup>46</sup> It has been hypothesized that the radial facet of the third carpal bone and the palmar aspect of the third metacarpal condyle undergo extreme bone formation to the point that the subchondral bone becomes ischemic and necrotic, resulting in collapse of the overlying articular cartilage.<sup>5</sup> The palmar metacarpal lesions, termed "traumatic osteochondrosis," as stated by Pool, are progressive, inoperable, and usually result in significant osteoarthritis even with supportive therapy.<sup>5,46</sup> The theories have been based on clinical impressions and evaluation of postmortem specimens, and no cause-effect relationship has been established.

Osteochondral fractures are often blamed on acute incidences, or "bad steps," although there is recent evidence to support that a chronic, progressive pattern of damage occurs at each of these sites.<sup>5</sup> Norrdin et al and Pool and Meagher have seen areas of bone resorption and osteoclastic activity in areas of osteochondral damage.<sup>5,55</sup> The theories surrounding the pathogenesis of osteochondral fractures and subchondral bone sclerosis in the horse are speculative, and little objective information exists concerning the effects of loads achieved at racing speeds on subchondral bone of young horses, or the normal progression of subchondral bone changes with exercise. Although microdamage formation has been suggested as an etiologic factor,<sup>5</sup> its role in the initiation of subchondral sclerosis, osteochondral fragmentation, and osteochondral fractures has not been determined.

## 5. Conclusions

The causes of osteochondral injuries in horses and man are difficult to determine, and even more difficult is detection of such injuries at an early stage. Various theories have stated that osteochondral disease, and osteoarthritis in particular, start at either the articular cartilage or subchondral bone, yet very few theories have focused on simultaneous changes in both tissues. The pathogenesis of such diseases must be determined for there to be any hope in identifying diagnostic means of early identification. At present, we do not know when certain changes in bone and cartilage become pathologic, or when certain changes are irreversible.

## IN DEPTH: CURRENT CONCEPTS IN EQUINE OSTEOARTHRITIS

## References

- Radin EL, Schaffler M, Gibson G, Tashman S. Osteoarthritis as the result of repetitive trauma. In: Kuettner KE, Goldberg VM, eds. *Osteoarthritic disorders*. Rosemont, IL: American Academy of Orthopaedic Surgeons 1995;197-204.
- Muller-Gerbl M. The subchondral bone plate. *Adv Anat Emb Cell Biol* 141:0-134.
- Duncan H, Jundt JW, Riddle JM, et al. The tibial subchondral plate. *J Bone Joint Surg* 1987;69:1212-1220.
- Milz S, Putz R. Quantitative morphology of the subchondral plate of the tibial plateau. *J Anat* 1994;185:103-110.
- Pool RR, Meagher DM. Pathologic findings and pathogenesis of racetrack injuries. In: Goodman NL, ed. *Veterinary clinics of north america-equine practice*. Philadelphia: W.B. Saunders Co. 1990;1-30.
- Frost HM. Structural adaptations to mechanical usage (SATMU): 1: Redefining Wolff's Law: The bone modeling problem. *Anat Rec* 1990;226:403-413.
- Burr DB, Martin RB, Schaffler MB, Radin EL. Bone modeling in response to in vivo fatigue microdamage. *J Biomech* 1985;18:189-200.
- Rubin CT, Lanyon LE. Osteoregulatory nature of mechanical stimuli: Function as a determinant for adaptive remodeling in bone. *J Orthop Res* 1987;5:300-310.
- Mori S, Burr DB. Increased intracortical remodeling following fatigue damage. *Bone* 1993;14:103-109.
- Burr DB, Schaffler MB. The involvement of subchondral mineralized tissues in osteoarthritis: Quantitative microscopic evidence. *Microsc Res Tech* 1997;37:343-357.
- Burr DB, Hoosier M. Alterations to the en bloc basic fuchsin staining protocol for the demonstration of microdamage produced in vivo. *Bone* 1995;17:431-433.
- Schaffler MB, Boyce TM, Fyhrle DP. Tissue and matrix failure modes in human compact bone during tensile fatigue. *Trans Orthop Res Soc* 1996;42:57-10.
- Noble BS, Stevens H, Loveridge N, Reeve J. Identification of apoptotic changes in osteocytes in normal and pathological human bone. *Bone* 1997;20:273-282.
- Qiu SJ, Hoshaw SJ, Gibson GJ, et al. Osteocyte apoptosis after acute matrix injury in compact bone. *Trans Orthop Res Soc* 1997;43:89-15.
- Wong SYP, Evans RA, Needs C, et al. The pathogenesis of osteoarthritis of the hip: Evidence for primary osteocyte death. *Clin Orthop Rel Res* 1987;214:305-312.
- Dunstan CR, Somers NM, Evans RA. Osteocyte death and hip fracture. *Connect Tissue Int* 1993;53:S113-S117.
- Radin EL, Paul IL, Lowry M. A comparison of the dynamic force transmitting properties of subchondral bone and articular cartilage. *J Bone Joint Surg* 1970;52-A:444-456.
- Radin EL, Paul IL. Importance of bone in sparing articular cartilage from impact. *Clin Orth Rel Res* 1971;78:342-344.
- Radin EL, Ehrlich MG, Chernack R, et al. Effect of repetitive impulsive loading on the knee joint of rabbits. *Clin Orth Rel Res* 1978;131:288-293.
- Kobayashi S, Takei T. Mechanical role of subchondral bone in protecting overlying articular cartilage. *Trans Orthop Res Soc USA, Japan, and Canada*. 1991;37:73.
- Eckstein F, Milz S, Anetzberger H, Putz R. The thickness of the subchondral mineralization zone in normal and arthrotic human patellae. *Trans Orthop Res Soc* 1996;42:245-241.
- Jacobs CR, Eckstein F, Merz B. Bicentric subchondral bone density patterns and trabecular orientation in incongruous joints are due to bending in the subchondral bone layer. *Trans Orthop Res Soc* 1998;44:546.
- Reilly GC, Currey JD, Goodship AE. Exercise of young Thoroughbred horses increases impact strength of the third metacarpal bone. *J Orthop Res* 1997;15:862-868.
- Duncan H, Riddle JM, Jundt JW, Pitchford W. Osteoarthritis and the subchondral bone plate. In: Verbruggen G, Veys EM, eds. *Degenerative joints*, vol 2. Amsterdam: Elsevier Sciences, 1987;181-197.
- Heegard JH, Carter DR, Beaupie GS. A mathematical model for stimulating mechanically modulated growth in developing diarthrodial joints. *Trans Orthop Res Soc* 1995;41:73.
- Mori S, Harruff R, Burr DB. Microcracks in articular calcified cartilage of human femoral heads. *Arch Pathol Lab Med* 1992;117:196-198.
- Sokoloff L. Microcracks in the calcified layer of articular cartilage. *Arch Pathol Lab Med* 1993;117:191-193.
- Radin EL, Burr DB, Fyrie D, et al. Characteristics of joint loading as it applies to osteoarthritis. In: Mow VC, Ratcliffe T, Woo SYL, eds. *Biomechanics of diarthrodial joints*, vol. 1. New York: Springer-Verlag, 1990;437-451.
- Hough AJ. Pathology of osteoarthritis. In: McCarty DJ, Koopman WJ, eds. *Arthritis and allied conditions*. Philadelphia, Lea & Febiger, 1993;1699-1721.
- Radin EL, Martin RB, Burr DB, et al. Effects of mechanical loading on the tissues of the rabbit knee. *J Orthop Res* 1984;2:221-234.
- Farkas TA, Boyd RD, Schaffler MB, et al. Early vascular changes in rabbit subchondral bone after repetitive impulsive loading. *Clin Orthop* 1987;219:259-267.
- Young DR, Richardson DW, Markel MD, Nunamaker DM. Mechanical and morphometric analysis of the third carpal bone of Thoroughbreds. *Am J Vet Res* 1991;52:402-409.
- Young DR, Nunamaker DM, Markel MD. Quantitative evaluation of the remodeling response of the proximal sesamoid bones to training-related stimuli in thoroughbreds. *Am J Vet Res* 1991;52:1350-1356.
- Estberg L, Stover SM, Gardner IA, et al. High-speed exercise history and catastrophic racing fractures in Thoroughbreds. *Am J Vet Res* 1996;57:1549-1555.
- McIlwraith CW, Yovich JV, Martin GS. Arthroscopic surgery for the treatment of osteochondral chip fractures in the equine carpus. *J Am Vet Med Assoc* 1987;191:531-540.
- Kawcak CE, McIlwraith CW. Proximodorsal first phalanx osteochondral chip fragmentation in 336 horses. *Equine Vet J* 1994;26:392-396.
- Colon JL, Bramlage LR, Hance SR, Embertson RM. Racing performance of Thoroughbred racehorses after arthroscopic removal of dorsoproximal first phalanx osteochondral fragments, in *Proceedings*. Am Assoc Equine Pract 1997;43:134-135.
- Rick MC, O'Brien TR, Pool RR, et al. Condylar fractures of the third metacarpal bone and third metatarsal bone in 75 horses: Radiographic features, treatments, and outcome. *J Am Vet Med Assoc* 1983;183:287-296.
- Bukowiecki CF, Bramlage LR, Gabel AA. Proximal sesamoid bone fractures in horses: Current treatments and prognosis. *Comp Cont Ed* 1985;7:S684-S670.
- DeHaan CE, O'Brien TR, Koblick PD. A radiographic investigation of third carpal bone injury in 42 racing thoroughbreds. *Vet Rad* 1987;28:88-92.
- Stephens PR, Richardson DW, Spencer PA. Slab fractures of the third carpal bone in Standardbreds and Thoroughbreds: 155 cases (1977-1984). *J Am Vet Med Assoc* 1988;193:353-358.
- Parente EJ, Richardson DW, Spencer P. Basal sesamoid fractures in horses: 57 cases (1980-1991). *J Am Vet Med Assoc* 1993;202:1293-1297.
- Mohammed HO, Hill T, Lowe J. Risk factors associated with injuries in Thoroughbred horses. *Equine Vet J* 1991;23:445-448.
- Johnson B. A look at racetrack breakdowns—1991. *J Equine Vet Sci* 1993;13:129-132.
- Wilson JH, Howe SB, Jensen RC, et al. Injuries sustained during racing at racetracks in the US in 1992, in *Proceedings*. Am Assoc Equine Practnr 1993;39:267.
- O'Brien TR, Hornof WJ, Meagher DM. Radiographic detection and characterization of palmar lesions in the equine fetlock joint. *J Am Vet Med Assoc* 1981;178:231-237.
- Young A, O'Brien TR, Pool RR. Exercise-related sclerosis in the third carpal bone of the racing thoroughbred. in *Proceedings*. Am Assoc Equine Practnr 1988;339-346.
- Jeffcoat LB, Rosedale PD, Freestone J, et al. An assessment of wastage in Thoroughbred racing from conception to 4 years of age. *Equine Vet J* 1982;14:185-198.

## IN DEPTH: CURRENT CONCEPTS IN EQUINE OSTEOARTHRITIS

49. Rosedale PD, Hopes R, Wingfield-Digby NJ, et al. Epidemiological study of wastage among racehorses: 1982 and 1983. *Vet Rec* 1985;116:66–69.
50. Palmer S. Prevalence of carpal fractures in Thoroughbred and Standardbred racehorses. *J Am Vet Med Assoc* 1986;188:1171–1173.
51. Bramlage LR, Schneider RK, Gobel AA. A clinical perspective on lameness originating in the carpus. *Equine Vet J* 1988;6(Suppl):12–18.
52. Kawcak CE, Bramlage LR, Embertson RM. Diagnosis and management of incomplete fracture of the distal palmar aspect of the third metacarpal bone in five horses. *J Am Vet Med Assoc* 1995;206:335–337.
53. Stover SM, Read DH, Johnson BJ, et al. Lateral condylar fracture histomorphology in racehorses, in *Proceedings. Am Assoc Equine Practnr* 1994;40:173.
54. Riggs CM, Whitehouse GH, Boyde A. Pathology of the distal condyles of the third metacarpal and third metatarsal bones of the horse. *Equine Vet J* 1999;31:140–148.
55. Norrdin RW, Kawcak CE, Capwell BA, McIlwraith CW. Subchondral bone failure in an equine model of overload arthritis. *Bone* 1998;22:133–139.