

Case 113004-02: 2 Year Old, Arab Gelding Sub-Chondral Bone Cyst Causing Lameness

On September 15, 2004, a 2 year-old Arabian gelding, was presented for a lameness of the right hind limb. Physical examination and regional anesthesia isolated the discomfort distal to the right hind fetlock joint and digital radiographic evaluation revealed a sagittal, proximal sub-chondral bone cyst (OCD lesion) of the second phalanx. The patient was discharged with instructions for stall rest and a re-evaluation in 60 days was scheduled. Follow up evaluation on November 24, 2004 revealed that the lameness had continued to worsen and that the sub-chondral bone cyst had increased in size (Fig 1). As the sub-chondral bone cyst was unlikely to spontaneously resolve, the owners elected to treat the affected joint with adipose derived regenerative cell therapy.

On November 29, 2004, the gelding was sedated and a local anesthetic was administered over the right hip, lateral to the tail-head. Fifteen grams of subcutaneous fat were removed by lipectomy, packaged, and sent via overnight courier for regenerative cell recovery. On December 1, 2004 the horse was anesthetized using a modified injectable induction protocol and maintained on isflourane and oxygen. The right rear limb was prepared using sterile technique and the affected region was desensitized using regional nerve anesthesia. Peri-articular access to the subchondral bone cyst was created using an orthopedic drill via a dorsal approach where 4.8 million cells were delivered utilizing bone marrow as a carrier agent. The delivery port was closed and the surgical site was closed using surgical skin staples.

Radiographic evaluation 36 days following regenerative cell therapy revealed significant improvement and greater than 50% increase in radio-opacity of the sub-chondral defect (Fig 2).

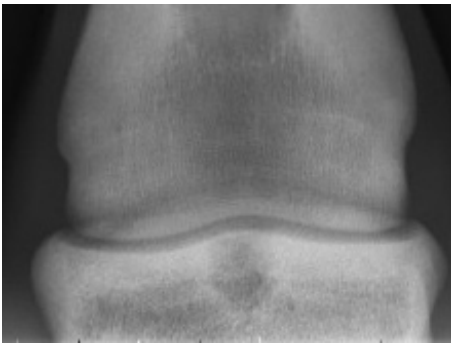


Figure 1 :
Proximal Sub-Chondral Bone
Cyst of the Second Phalanx
November 2004

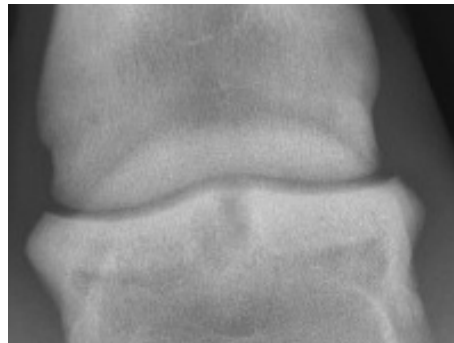


Figure 2 :
Proximal Sub-Chondral Bone
Cyst of the Second Phalanx
January 2005

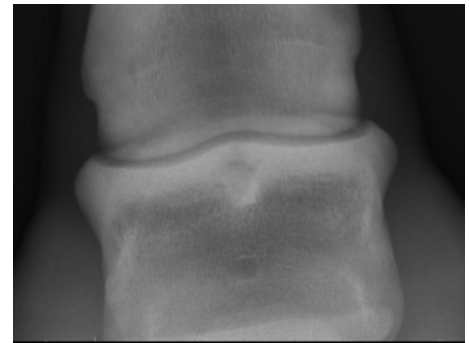

Figure 3 :
Proximal Sub-Chondral Bone
Cyst of the Second Phalanx
July 2005

The horse continued recommended physical therapy and returned to competitive activity within 45 days of stem cell therapy. Radiographic evaluation of the right hind limb in July 2005 revealed resolution of the subchondral defect. The underlying cancellous bone showed adequate opacity and the chondral surfaces showed no indication of compromise (Fig 3). At the time of this evaluation, the colt had returned to full activity and was actively competing.